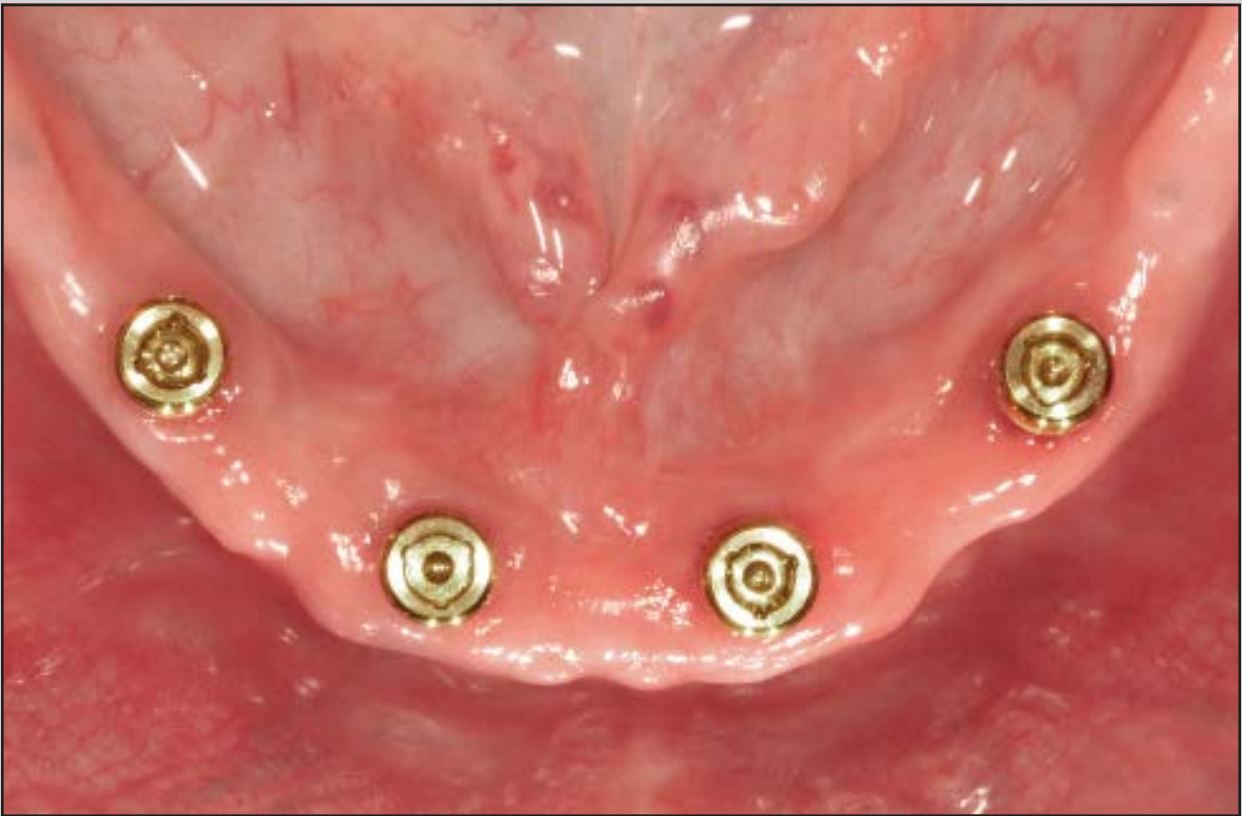
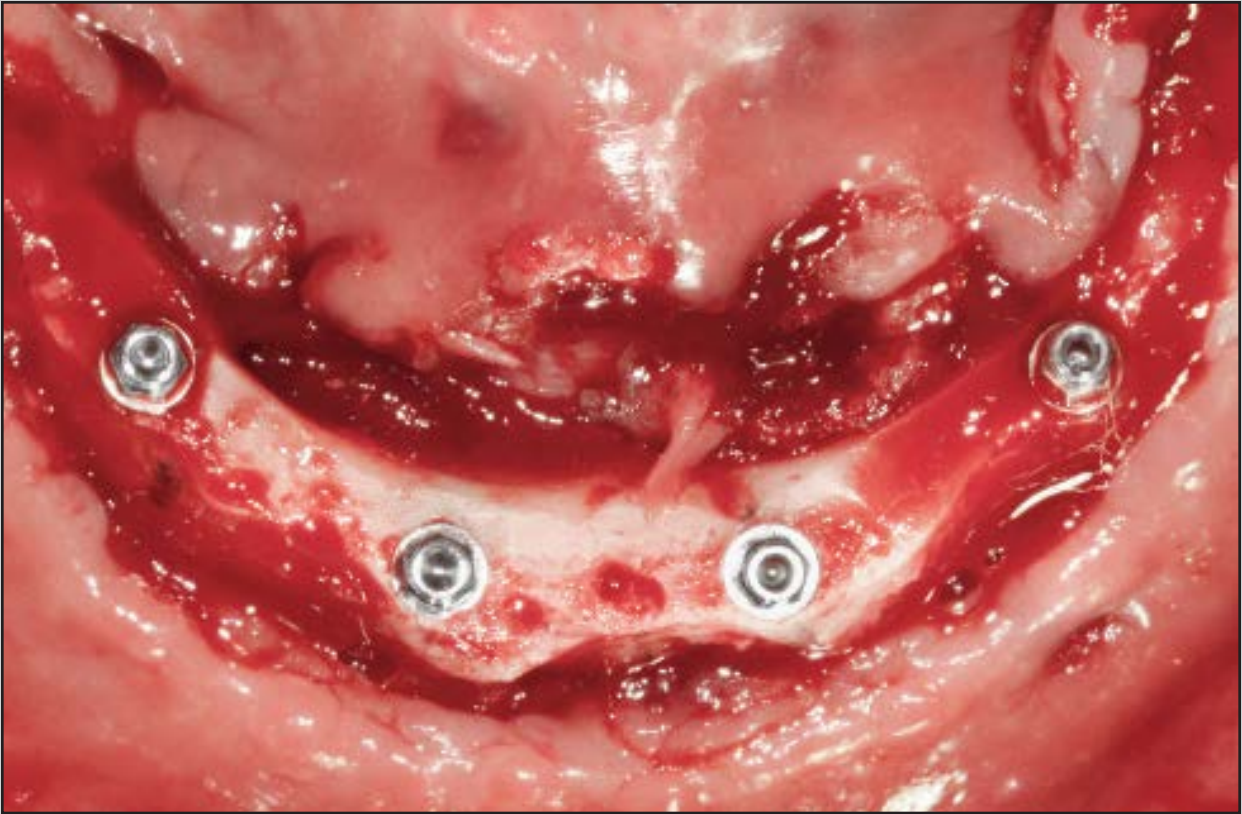
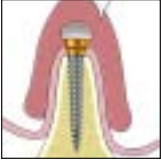# Flapped or Flapless Surgery for Narrow-Diameter Implant Placement for Overdentures: Advantages, Disadvantages, Indications, and Clinical Rationale



Michael D. Scherer, DMD, MS<sup>1</sup>  
 Andrew P. Ingel, DMD<sup>2</sup>  
 Nakul Rathi, BDS<sup>3</sup>

*Narrow-diameter implants for overdenture applications have gained in popularity due to their ability to be placed with simplified and less traumatic surgical protocols in limited-width alveolar ridges. The decision of whether to use a flapped or flapless procedure must be guided by a thorough evaluation and evidence-based diagnosis. This article reviews current principles relating to the use of narrow-diameter implants, along with the advantages and disadvantages of current surgical protocols. The indications for the use of each surgical procedure are demonstrated by case reports that highlight diagnosis, surgical planning, and final treatment outcomes. (Int J Periodontics Restorative Dent 2014;34(suppl):s89–s95. doi: 10.11607/prd.2169)*

Treatment options for dental implant therapy in conjunction with maxillary or mandibular removable prostheses typically involve the use of 2 to 4 larger, traditional diameter (> 3 mm) implants or a similar number of narrow-diameter (< 3 mm) implants. Although two traditional diameter implants remain the first choice for treatment of the edentulous mandible, some patients may be excluded from this therapy because of a lack of sufficient bone to accommodate an implant greater than 3 mm.<sup>1-3</sup> To place implants larger than 3 mm in diameter in such patients, alveolar ridge augmentation procedures such as onlay bone grafting, osteotomy enlargement, or ridge splitting are often carried out. Alternatively, ridge height reduction may be necessary. These procedures may elevate the risk of complications, increase morbidity, and/or prolong treatment times.<sup>3-5</sup> The use of narrow-diameter implants may obviate the need for bone augmentation procedures and enable a less invasive surgical protocol.<sup>6,7</sup>

Narrow-diameter implants for use in overdenture therapy can be

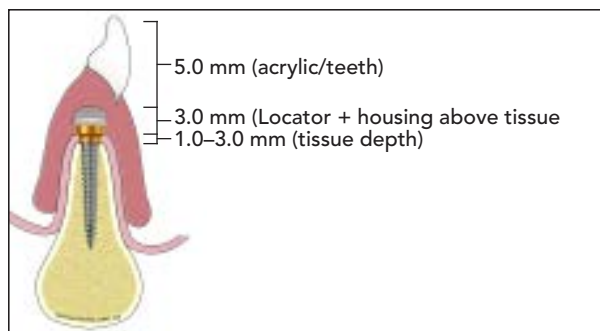
<sup>1</sup>Assistant Professor, School of Dental Medicine, University of Nevada, Las Vegas; Las Vegas, Nevada, USA; Advanced Prosthodontics, School of Dentistry, Loma Linda University, Loma Linda, California, USA.

<sup>2</sup>Assistant Professor, School of Dental Medicine, University of Nevada, Las Vegas; Las Vegas, Nevada, USA.

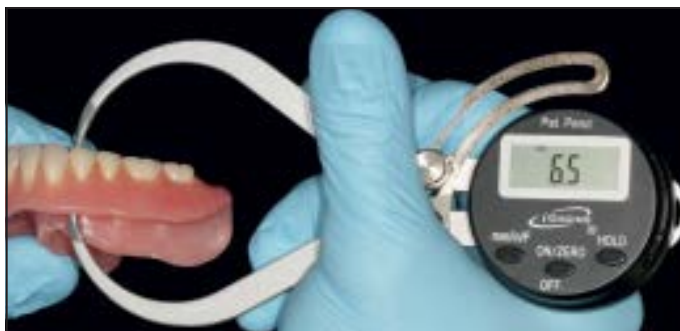<sup>3</sup>Graduate Prosthodontics Resident, College of Dentistry, Ohio State University, Columbus, Ohio, USA.

Correspondence to: Dr Michael D. Scherer, Advanced Prosthodontics, Loma Linda University School of Dentistry, 11092 Anderson Street, Room 3313, Loma Linda, CA 92350; fax: (209) 536-6554; email: mds@scherer.net.

©2014 by Quintessence Publishing Co Inc.



**Fig 1** Ideal prosthetic space values for Locator overdentures should be 9 mm to 11 mm, as measured from the alveolar crest to the height of the denture.



**Fig 2** Caliper measurement (6.5 mm) from the intaglio to occlusal surface is added to tissue depth, measured by bone sounding (3.0 mm); a sufficient amount of preoperative prosthetic space exists (9.5 mm).

placed using a flapped or flapless surgical procedure. Although both techniques have been advocated, debate exists as to when one technique should be chosen over the other.<sup>8</sup> This article aims to describe the advantages, disadvantages, and indications of both procedures for placing narrow-diameter implants for overdentures.

### Surgical procedure criteria

An important first step in determining whether a denture patient is a candidate for a flapped or flapless surgical procedure is to evaluate the prosthetic volume of the patient's existing complete denture. *Prosthetic volume*, also known as restorative space, is defined as the amount of space available to receive the proposed restoration; it is bound by the occlusal plane, supporting tissues of the edentulous arch, and nonsupporting tissues such as the cheeks, tongue, and lips.<sup>9</sup> The minimum height needed for a Locator attachment (Zest Anchors) and hous-

ing is 9 mm from the crest of the bone to the height of the denture (Fig 1).<sup>10</sup> One method of assessing this space is to use a caliper to measure a point from inside the intaglio surface to the occlusal surface of the complete denture (Fig 2). The caliper measurement should be a minimum of 6 mm to ensure that enough denture material exists to accommodate the Locator attachment and housing complex. If the caliper measurement is less than 6 mm, insufficient room exists to accommodate the attachment and housing complex, and reflection of a surgical flap followed by ridge height reduction is indicated.

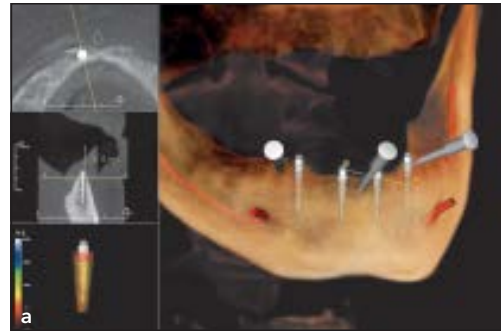
An alternative approach to measuring prosthetic volume requires the assistance of cone beam computed tomography (CBCT) imaging and the application of soft tissue separation methods. Cotton rolls are placed surrounding the buccal and lingual cameo surface of the complete denture, creating air space around the denture acrylic resin. Having such space allows for visualization of the denture outline without the need for a radiopaque

medium such as barium sulfate or gutta percha. Virtual measurements can be made from the restoration outline to the proposed implant position, giving a reliable assessment of prosthetic volume (Figs 3a and 3b). If the measurement as determined by the CBCT is less than 9 mm, surgical alveolar ridge height reduction with flap elevation is indicated.

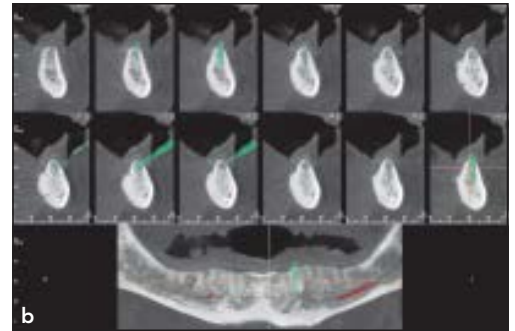
Bone conformation is another important factor in the clinical decision of whether to elevate a flap. Patients who have had recent extractions typically present with incomplete or delayed healing or, in some cases, damaged alveolar bony processes from the extraction procedures. When the residual bone is tortuous, sharp, and has insufficient width to accommodate at least 1 mm of bone fully surrounding the implant, reflection of a flap is indicated (Figs 4a and 4b). This type of clinical/radiographic presentation will necessitate alveolar ridge recontouring due to the need for sufficient alveolar bone dimensions surrounding the implant. In contrast, patients who present with



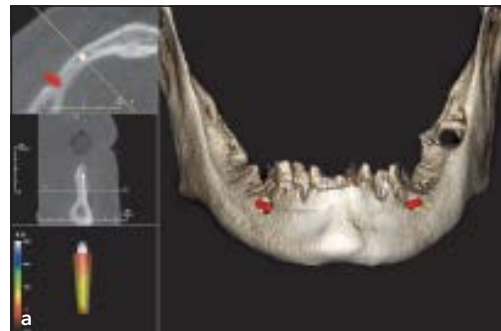**Fig 3a** Rounded alveolar ridge with sufficient distance from implant platform to denture allows for flapless implant placement surgery.



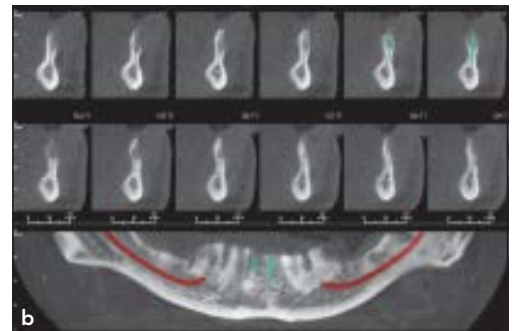
**Fig 3b** CBCT image showing cross-section of well-healed, rounded alveolar ridge.



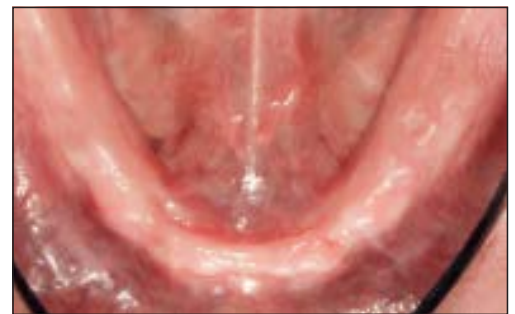**Fig 4a** Sharp projections and a narrow anterior ridge are indications for flap elevation surgical procedures.



**Fig 4b** CBCT image showing cross-section of bottle-shaped, narrow alveolar ridge with incomplete healing.



**Fig 5** Alveolar ridge examination reveals a well-healed, resorbed alveolar ridge with little undercut, indicating an ideal candidate for flapless implant placement surgery.



large, u-shaped, and well-healed alveolar ridges of sufficient height and width are more favorable candidates for flapless surgical procedures (Fig 5).

### Flapless implant placement

A 70-year-old man presented with concerns about his loose mandibular denture and gingival irritation. He had been wearing a mandibular denture for several years but had

never successfully accommodated to wearing a complete denture. The denture was evaluated for occlusion, vertical dimension, and wear, and was found to be clinically acceptable.<sup>11</sup>

Evaluation of the mandibular alveolar ridge revealed a healed, moderately atrophic ridge with adequate keratinized soft tissues. The patient's denture was initially assessed for adequate prosthetic volume using a combination of a measurement caliper and peri-

odontal probe bone sounding. A CBCT scan was performed with the patient wearing his mandibular denture relined with a radiopaque polyvinyl siloxane material (Green-Mousse, Parkell) and using soft tissue separation techniques. The radiographic files were imported into CBCT interpretation software (Invivo, Anatomage), the inferior alveolar nerve was marked, and virtual implants were placed. Measurements made from the implant platform to the superior surface

**Table 1** Indications for a flapped or flapless procedure for implant and overdenture placement

Indications	
Flapless	<ul style="list-style-type: none"> <li>• Bone conformation is smooth and rounded, and width is adequate</li> <li>• Adequate prosthetic volume from bone to restoration</li> <li>• Medical history: blood thinners, medically compromised, or other significant comorbidities may limit sizable surgical procedures</li> <li>• Immediate loading</li> <li>• Enhanced patient comfort</li> </ul>
Flapped	<ul style="list-style-type: none"> <li>• Irregular alveolar bone; reshaping required</li> <li>• Insufficient prosthetic volume requiring reduction of bone height</li> <li>• Direct visual access preferred</li> </ul>

of the complete denture gave a more precise assessment of prosthetic volume. Four 2.9 × 12 mm Zest Locator Overdenture Implants (Biomet 3i) were chosen, two for the lateral incisor region and two for the first premolar region, and the decision was made to use a flapless surgical procedure (Table 1).

Based upon the CBCT scan with implant virtual plan, a surgical guide (Anatomage) was fabricated to assist in placement of the implants (Fig 6a). The guide was firmly adapted to the mandibular alveolar ridge using anchor pins. To mark the implant osteotomy sites, an initial 1.2-mm pilot osteotomy was created through the guide using a 6-mm drill stop and a 3.7-mm sleeve insert. A self-guided rotary tissue punch was used through the initial osteotomies, and the tissue was carefully excised. Sequential implant osteotomies were performed using a 1.6-mm drill with a 12-mm drill stop and a 2.1-mm drill with an 8-mm drill stop. Using the shorter drill stop for the last drill creates a step in the osteotomy that allows the self-tapping implant

to engage slightly undersized apical bone. Implants were placed through the surgical guide, and final insertion torque values greater than 35 Ncm were confirmed with the assistance of a spring-style manual torque wrench.

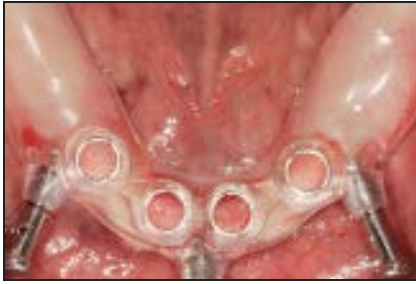Four 2.5-mm Locator attachments were placed on the implants and hand-tightened (Fig 6b). A panoramic radiograph was taken to verify the implant positions and complete adaptation of the Locator attachments to the implant platforms. The patient's denture was modified, the Locator attachments were torqued to 30 Ncm, and the housings were attached to the denture using a chairside hard reline material (Zest Anchors). The black processing inserts were removed from the housings and extralight extended range nylon males were placed.

The patient was instructed to maintain a soft diet for 6 to 8 weeks, wear the denture as much as possible throughout the day, and clean it daily. After 1 week, the peri-implant soft tissue appearance was excellent, no im-

plant mobility was evident, and plaque formation was minimal (Fig 6c). Optimal denture stability was achieved, and the patient indicated that his ridge soreness was eliminated. No additional prosthodontic intervention was required, and the original inserts placed the day of surgery remained effective throughout recall visits. A panoramic radiograph was made confirming adequate implant healing and alveolar bone fill (Fig 6d).

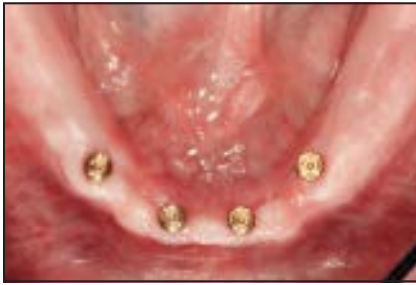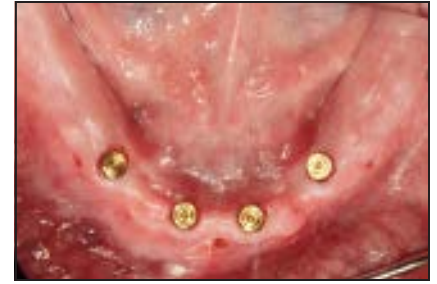### Flap elevation implant placement

A 75-year-old man presented with complaints about the looseness of his mandibular complete denture and soreness upon inserting and removing the prosthesis. He expressed interest in dental implants. Examination of the existing complete denture indicated that it was clinically acceptable for conversion to an implant-retained overdenture.<sup>11</sup> However, a caliper used to measure the prosthetic volume revealed insufficient prosthetic space. An unfavorable alveolar ridge conformation also confirmed the need for a flapped procedure (Fig 7a). Clinical evaluation determined the presence of substantial facial and lingual undercuts and a mandibular ridge form that required preprosthetic surgery. A CBCT scan was performed to enhance visualization of the alveolar ridge. It confirmed that the mandibular ridge exhibited incomplete healing, and the alveolar profile was sharp and irregular.



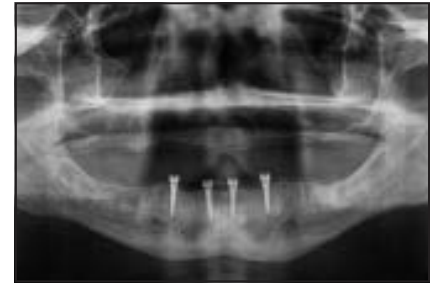**Fig 6a** (left) CBCT surgical guide adapted to the residual ridge.

**Fig 6b** (right) Implants placed using a flapless surgical procedure.



**Fig 6c** (left) Soft tissue at 1 week shows optimal healing after flapless surgical procedure.

**Fig 6d** (right) Radiograph illustrating adequate implant healing and alveolar bone fill.



The authors determined that 5 mm of alveolar ridge reduction was necessary to ensure sufficient alveolar ridge width and prosthetic space. Four 2.4- × 12-mm overdenture implants (Zest LODI) were chosen, two for the lateral incisor region and two for the first premolar region.

Flap elevation was performed with a surgical scalpel and periosteal elevators, elevating enough tissue facial and lingual to the proposed sites to fully visualize the alveolar ridge contours (Fig 7b). The alveolar ridge height was reduced using surgical acrylic burs. A midline osteotomy site was prepared with a 1.2-mm-diameter pilot osteotomy drill to a depth of 6 mm, and a paralleling pin was placed to facilitate parallelism between the four implants. With the assistance of a surgical guide fabricated from a duplicate of the patient's mandibular denture, sequential

osteotomies were performed using the 1.2-mm drill with a 12-mm drill stop and the 1.6-mm drill with an 8-mm drill stop. The implants were placed, and insertion torque values exceeding 35 Ncm were confirmed with the assistance of a spring-style manual torque wrench (Fig 7c). Four 2.5-mm Locator attachments were placed and torqued to 30 Ncm. The tissue was reapproximated with alternating 3-0 chromic gut and 4-0 vicryl interrupted sutures to allow for minimal closure tension on the tissues.

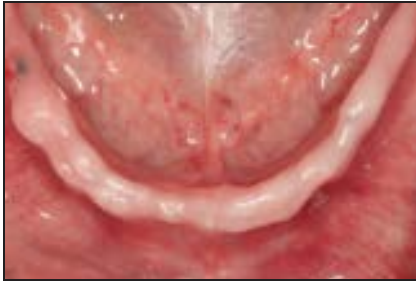A soft tissue liner (Coe-Soft, GC America) was applied to the intaglio surface of the denture. The patient's existing denture required only minimal adjustment because the room for the attachments was adequate as a result of the alveolar ridge reduction.

The patient was reevaluated weekly. After 8 weeks of healing, integration was confirmed with ra-

diographs, percussion, and stability testing (Fig 7d). A panoramic radiograph was taken to verify adequate healing and bone formation around the implants (Fig 7e). A laboratory-processed hard reline procedure was performed with the Locator attachments incorporated into the denture. The processing males were replaced with light (blue) nylon male inserts, and wear and care instructions were reinforced.

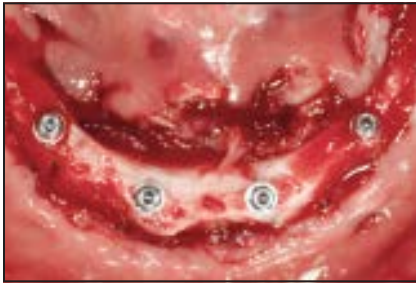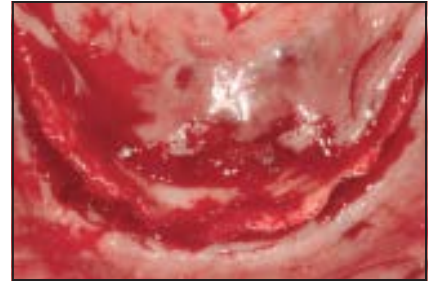## Discussion

Narrow-diameter dental implants were developed as a minimally invasive, low-cost alternative to larger diameter implants. Although originally advocated for provisional or interim purposes, they have shown cumulative survival rates comparable to those of larger, traditional implants and are becoming a popular option for definitive prosthodontic

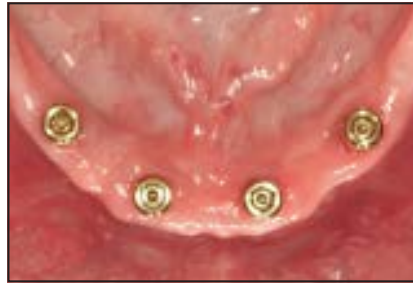

**Fig 7a** (left) Sharp and undercut mandibular ridge poses a challenge for implant placement without alveolar recontouring.

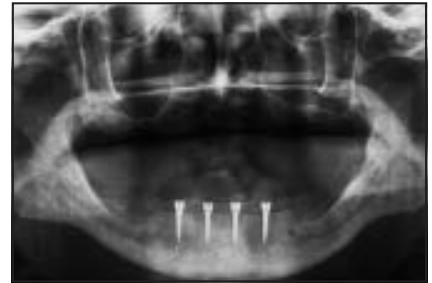**Fig 7b** (right) Flap elevation illustrating sharp and tortuous alveolar ridge requiring recontouring prior to implant placement.



**Fig 7c** Alveolar reduction is completed after flap elevation and implants are placed in the lateral incisor and first premolar regions.



**Fig 7d** Soft tissue appearance after 8 weeks.



**Fig 7e** Radiograph illustrating adequate alveolar healing and bone formation around the implants.

treatment.<sup>3,8,12-16</sup> Some authors advocate the use of 2 to 4 narrow-diameter implants with a moderately roughened surface to improve fixation within bone, ensure high levels of bone-to-implant contact, and improve long-term results.<sup>15,17-19</sup>

The decision of whether to place narrow-diameter implants with a flapped or flapless surgical technique has not been closely examined in the literature. With flapped procedures, surgical access is achieved by making an incision through the tissues down to the bone, elevating a full-thickness flap, including the periosteum, and directly visualizing the alveolar bone volume prior to osteotomy preparation. Advantages of flap elevation include considerably enhanced surgical visibility and control. Bone and soft tissue can be recontoured, and keratin-

ized tissues can be preserved.<sup>14,20</sup> Disadvantages include the need for greater surgical access, the potential for delay in tissue recovery and healing, and increased bone loss.<sup>20,21</sup>

Flapless surgical procedures are typically performed transmucosally, without elevating the soft tissue covering the alveolar bone. The main benefit of this approach is the reduced amount of tissue trauma that is incurred as the periosteum layer remains intact. Not disturbing the periosteum layer allows for a greater chance to preserve alveolar bone levels, improve blood supply to the implant site, and reduce patient discomfort.<sup>21</sup> However, flapless procedures tend to be more difficult due to the inability of the surgeon to directly visualize anatomical landmarks and vital structures; the learning curve is steeper.<sup>20</sup> Adequate irrigation

to the osteotomy can be challenging,<sup>22</sup> although recent findings suggest this may not be as important as previously thought.<sup>23</sup>

Some authors have reported relatively high levels of short- and long-term clinical success for narrow-diameter implants placed using flapless surgical procedures.<sup>15,16,24</sup> However, their incidence in one study population was less than 17%.<sup>3</sup> Some authors advocate both approaches.<sup>3,8</sup>

The cases presented here represent typical examples of each approach. Both patients were good candidates for denture stabilization using narrow-diameter implants. However, a complete diagnostic evaluation revealed two distinctly different sets of conditions requiring distinct surgical approaches. The first patient presented with good prosthetic space. The remaining bone had sufficient width



and height as determined both by clinical exam and CBCT analysis. Following the criteria previously established, these features allowed for minimally invasive surgery using a flapless approach and facilitated immediate loading.

The irregular and tortuous topography of the second patient's interforaminal area meant that a flapless approach was contraindicated. In addition, without bony reduction, the result would have presented a prosthetic challenge due to limited space for the denture attachment housing. Therefore, the surgical protocol consisted of full flapped exposure of the implant sites, interforaminal bony reduction, implant placement, and suture closure. The denture was not immediately loaded despite good intraoperative torque values.

## Conclusions

The use of narrow-diameter implants for stabilizing dentures shows promising long-term results but requires a thoughtful and careful preoperative protocol. Thorough patient assessment and treatment planning are crucial. The prosthetic space and bone conformation should be analyzed using a caliper and radiographic imaging, such as CBCT. The clinician's surgical and prosthetic skills must also be considered, along with whether flap elevation or a flapless surgical procedure would most likely optimize the prospects for long-term success.

## Acknowledgments

The authors reported no conflicts of interest related to this study.

## References

1. Feine JS, Carlsson GE, Awad MA, et al. The McGill consensus statement on overdentures. Mandibular two-implant overdentures as first choice standard of care for edentulous patients. *Int J Oral Maxillofac Implants* 2002;17:601–602.
2. Thomason JM, Kelly SA, Bendkowski A, Ellis JS. Two implant retained overdentures: A review of the literature supporting the McGill and York consensus statements. *J Dent* 2012;40:22–34.
3. Preoteasa E, Melescanu-Imre M, Preoteasa CT, Marin M, Lerner H. Aspects of oral morphology as decision factors in mini-implant supported overdenture. *Rom J Morphol Embryol* 2010;51:309–314.
4. al-Ansari BH, Morris RR. Placement of dental implants without flap surgery: A clinical report. *Int J Oral Maxillofac Implants* 1998;13:861–865.
5. Oh TJ, Shotwell J, Billy E, Byun HY, Wang HL. Flapless implant surgery in the esthetic region: Advantages and precautions. *Int J Periodontics Restorative Dent* 2007;27:27–33.
6. Davarpanah M, Martinez H, Tecucianu JF, Celletti R, Lazzara R. Small-diameter implants: Indications and contraindications. *J Esthet Dent* 2000;12:186–194.
7. Griffiths TM, Collins CP, Collins PC. Mini dental implants: An adjunct for retention, stability, and comfort for the edentulous patient. *Oral Surg Oral Med Oral Pathol Oral Radiol Endod* 2005;100:81–84.
8. Sohrabi K, Mushantat A, Esfandiari S, Feine J. How successful are small-diameter implants? A literature review. *Clin Oral Implants Res* 2012;23:515–525.
9. Ahuja S, Cagna DR. Classification and management of restorative space in edentulous implant overdenture patients. *J Prosthet Dent* 2011;105:332–337.
10. Lee CK, Agar JR. Surgical and prosthetic planning for a two-implant-retained mandibular overdenture: A clinical report. *J Prosthet Dent* 2006;95:102–105.
11. Sato Y, Tsuga K, Akagawa Y, Tenma H. A method for quantifying complete denture quality. *J Prosthet Dent* 1998;80:52–57.
12. Christensen GJ. The “mini”-implant has arrived. *J Am Dent Assoc* 2006;137:387–390.
13. el Attar MS, el Shazly D, Osman S, el Domiati S, Salloum MG. Study of the effect of using mini-transitional implants as temporary abutments in implant overdenture cases. *Implant Dent* 1999;8:152–158.
14. Becker W, Goldstein M, Becker BE, et al. Minimally invasive flapless implant placement: Follow-up results from a multicenter study. *J Periodontol* 2009;80:347–352.
15. Elsyad MA, Gebreel AA, Fouad MM, Elshoukoui AH. The clinical and radiographic outcome of immediately loaded mini implants supporting a mandibular overdenture. A 3-year prospective study. *J Oral Rehabil* 2011;38:827–834.
16. Bidra AS, Almas K. Mini implants for definitive prosthodontic treatment: A systematic review. *J Prosthet Dent* 2013;109:156–164.
17. Froum SJ, Simon H, Cho SC, et al. Histologic evaluation of bone-implant contact of immediately loaded transitional implants after 6 to 27 months. *Int J Oral Maxillofac Implants* 2005;20:54–60.
18. Sadowsky SJ. Mandibular implant-retained overdentures: A literature review. *J Prosthet Dent* 2001;86:468–473.
19. Wennerberg A, Albrektsson T, Lausmaa J. Torque and histomorphometric evaluation of cp titanium screws blasted with 25- and 75-microns-sized particles of Al<sub>2</sub>O<sub>3</sub>. *J Biomed Mater Res* 1996;30:251–260.
20. Campelo LD, Camara JR. Flapless implant surgery: A 10-year clinical retrospective analysis. *Int J Oral Maxillofac Implants* 2002;17:271–276.
21. Sunitha RV, Sapthagiri E. Flapless implant surgery: A 2-year follow-up study of 40 implants. *Oral Surg Oral Med Oral Pathol Oral Radiol* 2013;116:e237–e243.
22. Sclar AG. Guidelines for flapless surgery. *J Oral Maxillofac Surg* 2007;65:20–32.
23. Jeong SM, Yoo JH, Fang Y, Choi BH, Son JS, Oh JH. The effect of guided flapless implant procedure on heat generation from implant drilling [epub ahead of print]. *J Craniomaxillofac Surg* 2013 Nov 14. doi: 10.1016/j.jcms.2013.11.002.
24. Shatkin TE, Petrotto CA. Mini dental implants: A retrospective analysis of 5640 implants placed over a 12-year period. *Compend Contin Educ Dent* 2012;33:2–9.