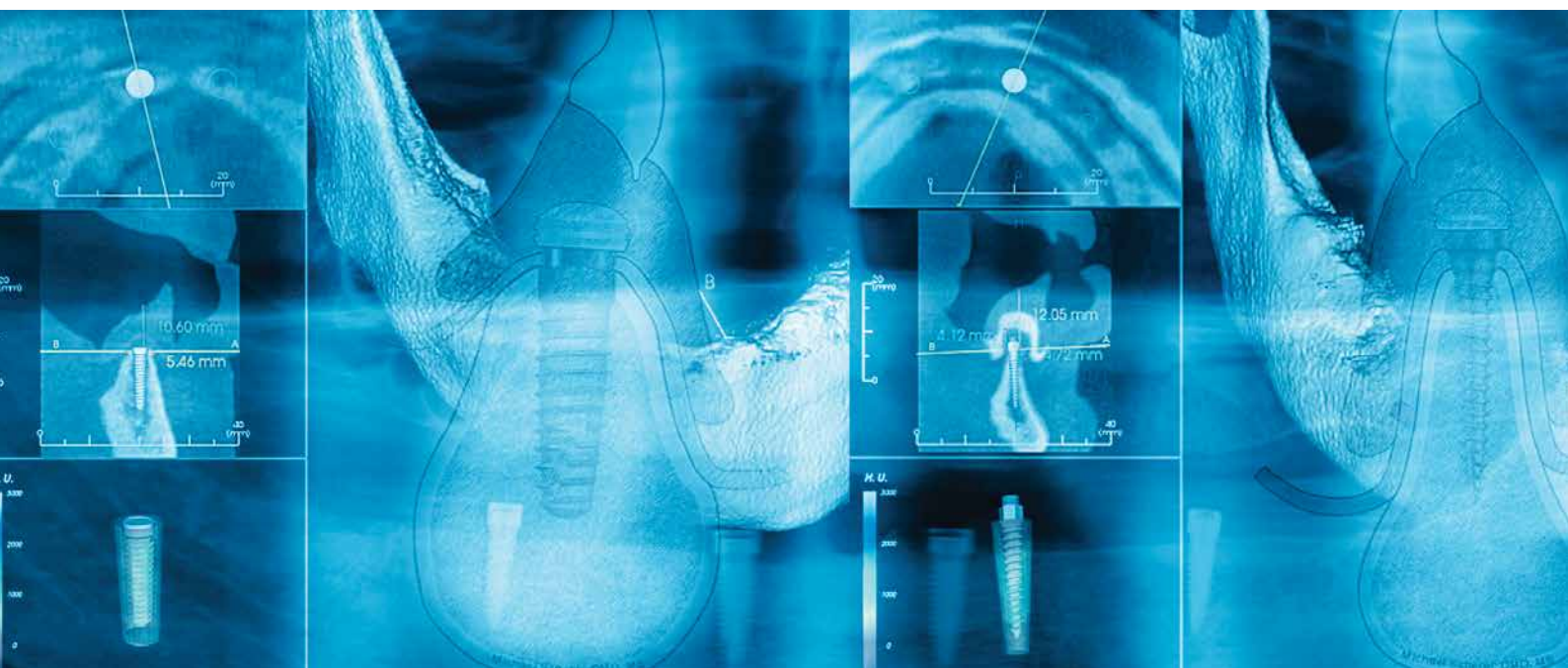



SPECIAL REPRINT, JIRD[®] CE Article No. 2, 2015

Inside this issue:

Guidelines for implant overdenture treatment with standard or narrow diameter implants: A clinical rationale

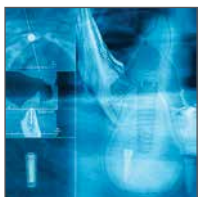Michael D. Scherer, DMD, MS

Flapless placement of four narrow diameter implants to immediately stabilize a loose mandibular denture

Michael D. Scherer, DMD, MS & Andrew P. Ingel, DMD

Guidelines for implant overdenture treatment with standard or narrow diameter implants: A clinical rationale

Michael D. Scherer, DMD, MS†



Debate exists over whether standard or narrow diameter dental implants should be used for implant overdenture therapy. This article reviews the characteristics of each, principles relating to the use of standard or narrow diameter implants, and indications for each type. Additionally, a decision tree to aid with choosing between standard or narrow diameter implants is presented.

Key Words: narrow diameter implants, overdenture, standard diameter implants, clinical guidelines

Introduction

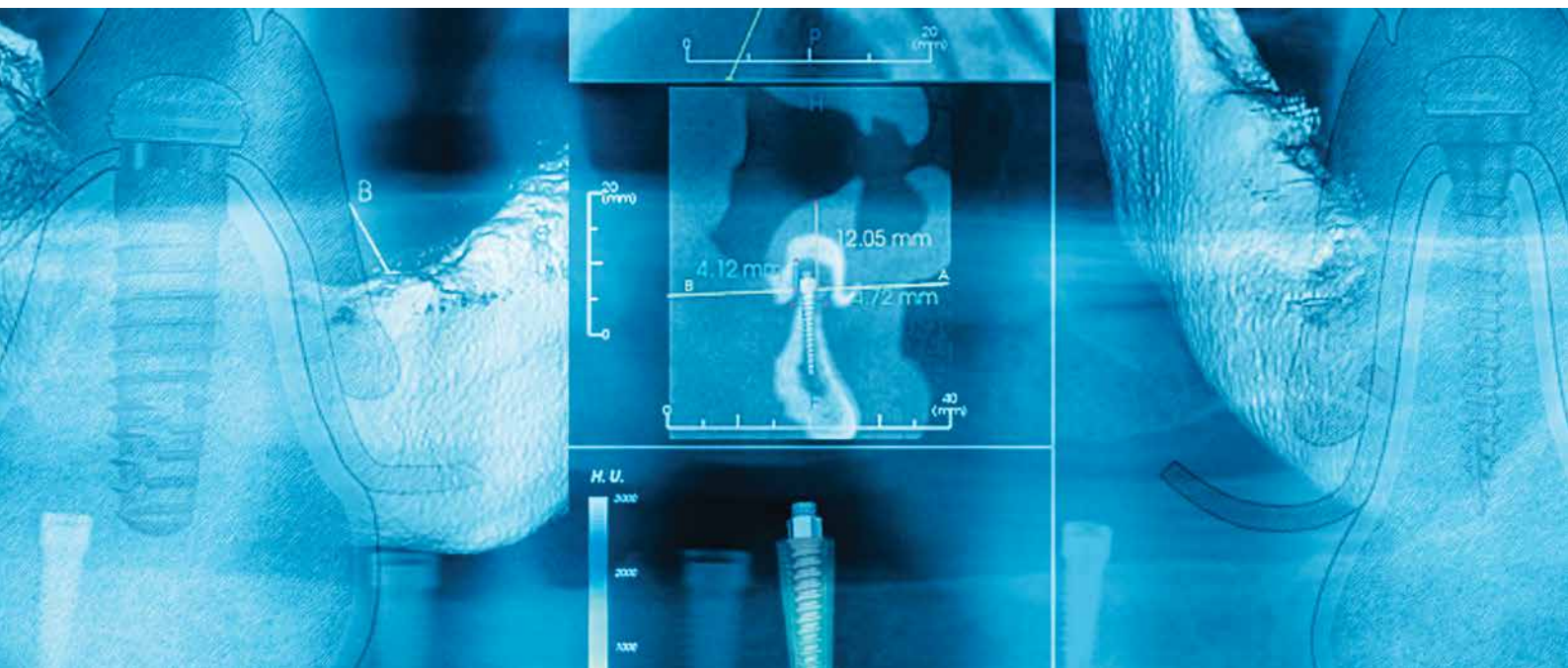
Tooth loss is multifactorial and often results from a complex interaction of comorbidities that, left unresolved, may progress to complete edentulism.¹ Edentulism is considered a chronic oral disease that is a terminal outcome of the interplay between biological and non-biological processes. It ultimately results in physical impairment, disability, and handicap.² While the rate of edentulism has been decreasing throughout the past three decades, the increase in the older population has resulted in an increased total number of edentulous people.³ These older “baby boomers” tend to have significantly higher levels of edentulism, with the number of edentulous arches expected to rise from 57 million in 2000 to 61 million in 2020.⁴ As a result, the demand for treatment will increase.

The traditional treatment for edentulism has been the fabrication of removable, tissue-supported complete dentures.⁵ Historically, one of the greatest challenges

facing dentists has been to provide removable prostheses that have adequate retention and stability.⁶⁻⁸ The use of dental implants to retain and/or support removable prostheses is a well-accepted treatment option with long-term successful outcomes.⁹⁻¹² As a result, implant overdenture therapy is considered to be the first choice standard of care for the edentulous mandible.¹³⁻¹⁵

Implant Overdenture Treatment Overview

Treatment options for dental implant therapy in conjunction with mandibular removable prostheses typically involve the use of two to four standard diameter implants (>3mm) placed in the anterior mandible (Fig. 1). Implants are traditionally placed into the interforaminal portion of the mandible, with distal implants placed 5mm anterior to the mental foramen and mesial implants placed 3.5mm distal to the midline.¹⁶⁻¹⁹ These positions correspond to the first premolar and lateral incisor sites. Implant placement in this region is common, as many



edentulous patients exhibit substantial posterior alveolar ridge resorption with limited bone volume to accommodate implants above the inferior alveolar canal. Additionally, the anterior mandible typically has limited critical anatomy such as nerves and blood vessels, and the average bone quality is higher and denser than posterior sites.²⁰⁻²²

Maxillary implant overdentures typically are supported by four to six standard diameter implants spread more evenly throughout the arch (Fig. 2). The implants are traditionally placed in the first molar, first premolar, and canine sites, which have greater bone volume and require less angulation than more anterior locations. If the sinus anatomy and surgical access permit placement in the posterior region, many clinicians advocate placement as posteriorly as possible to maximize the number and distribution of implants.²³

Characteristics of Standard and Narrow Diameter Implants

While many authors advocate using standard diameter implants as the first choice for treatment of the edentulous arch, some patients may be excluded from this therapy because of a lack of sufficient bone to accommodate an implant with a diameter greater than 3mm.²⁴ To place implants greater than 3mm in diameter in such patients, additional surgical procedures may be necessary such as onlay bone grafting, osteotomy enlargement, or ridge splitting. Alternatively, a clinician can gain access to more ridge width by using ridge-height reduction procedures, as the mandibular bone becomes wider inferiorly. However,

all these procedures may elevate the risk of complications, increase morbidity, and/or prolong treatment times.²⁴⁻²⁶ The placement of narrow dental implants may reduce the need for these more complex surgical procedures.

Table 1 summarizes the differences between standard and narrow diameter dental implants for implant overdenture therapy. Standard diameter implants are larger, with more overall surface area and often have a more conservative thread design. In contrast, while both traditional and contemporary narrow diameter implants are smaller and have less overall surface area than standard diameter implants, traditional narrow diameter implants are a one-piece design with less aggressive threads. The contemporary narrow diameter implant designs often feature aggressive threads and a two-piece design, typically accepting only one type of abutment, such as a LOCATOR® Abutment (Manufactured by Zest Anchors, Distributed by BIOMET 3i, Palm Beach Gardens, Florida, USA).

The number of prosthetic options also distinguishes standard from narrow diameter implants. The two-piece design of standard diameter implants enables them to accept more types of abutments and restorative platforms (Fig. 3). In addition to full-arch removable prostheses, standard diameter implants can also be used to support single and multiple fixed implant restorations. Also, if a younger patient gets one type of treatment and later in life decides to convert to another type of restoration, standard diameter implants will facilitate this conversion.²⁷

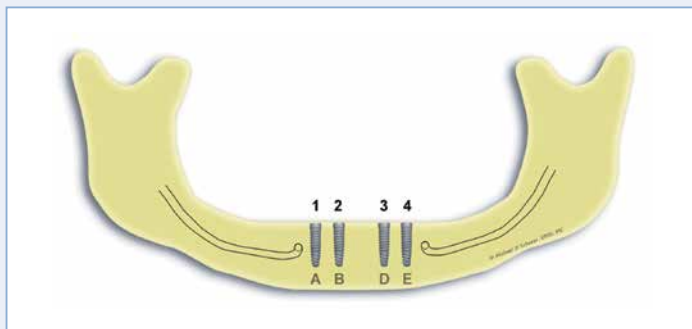


Fig. 1. For mandibular overdentures, two to four implants are typically positioned in the anterior; as shown.

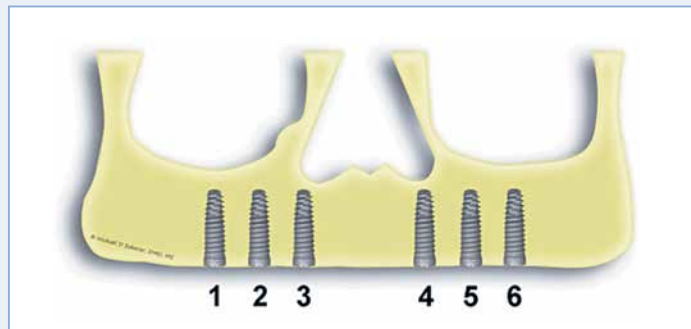


Fig. 2. For maxillary overdentures, four to six implants for overdentures are typically distributed more evenly throughout the arch, as shown.

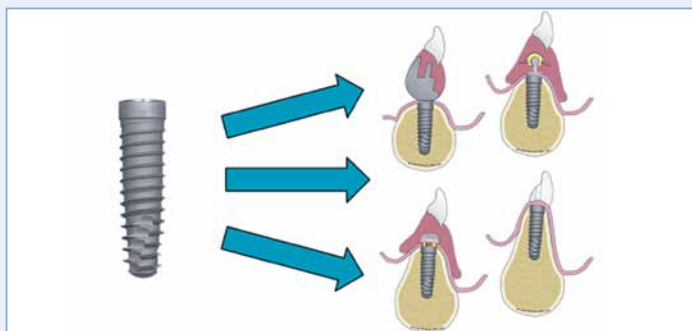


Fig. 3. Standard diameter implants offer multiple prosthetic options, including fixed single and full-arch multiple-unit restorations, and removable restorations with either bar or LOCATOR® Abutments.

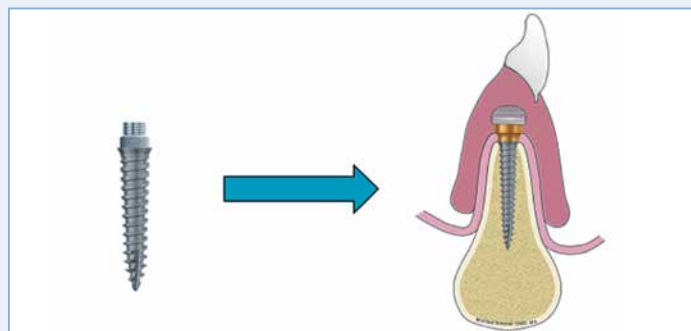


Fig. 4. Narrow diameter implants are typically used only to retain full-arch removable restorations.

For example, if a middle-aged patient is treated with two standard diameter implants to retain an implant overdenture, he or she can have additional implants placed and convert to a fixed implant restoration later in life.

In contrast, the prosthetic options for narrow diameter implants are limited. Most systems typically permit use only with a full-arch removable prosthesis (Fig. 4). For older patients who are generally satisfied with a removable prosthesis and are principally interested in denture stabilization, narrow diameter implants are a good alternative. Many of these older patients also tend to have increasingly complex medical histories and would benefit from a minimally invasive surgical approach.

Bone Volume and Implant Diameter

Having adequate bone around any implant helps to ensure the implant's osseointegration and long-term clinical stability and preserve the crestal bone. Generally

accepted clinical guidelines regarding peri-implant bone volume have been established.²⁸⁻³⁰ On average, more than 1.0-1.5mm of alveolar bone should surround the implant to ensure proper blood supply and minimize alveolar remodeling and crestal bone resorption. These recommendations stem from the observation that .5mm to 1.59mm of bone loss can result from implant placement using a flap procedure.³¹⁻³⁴

Variations in bone width in the edentulous arch can be influenced by the location (anterior or posterior), the length of time the patient has been edentulous, and any history of periodontal disease. Average crestal mandibular bone width has been reported as 3.64mm ± 1.83mm in the anterior region, 4.82mm ± 2.16mm in the premolar region, and 6.02mm ± 1.67mm in the molar region.³⁵ Maxillary bone widths are similar except in the molar region, where the bone tends to be significantly wider. In contrast, average mandibular bone width 3mm below

Implant Characteristics	
Standard Diameter	Narrow Diameter
<ul style="list-style-type: none"> • Diameter greater than 3mm • Greater overall surface area • Varying thread design • Two-piece design • One-stage or submerged healing • Internal connection • Platform switching • Accepts multiple abutments and a variety of prosthetic parts and tissue-cuff heights • For fixed single restorations, overdentures, and full-arch fixed solutions 	<ul style="list-style-type: none"> • Diameter less than 3mm • Less overall surface area • Conservative or aggressive thread design • One- or two-piece design • Unsubmerged healing • External connection • No platform switching • Two-piece design accepts only a LOCATOR® Abutment and one of two tissue-cuff heights • Recommended for full-arch removable restorations

Table 1: Characteristics of standard versus narrow diameter dental implants for overdenture therapy.

Recommended Widths	
Implant Diameter (mm)	Bone Width (mm)
2.4	5.4
2.9	5.9
3.25	6.4
4.0	7.0

Table 2: Recommended buccolingual widths for implant overdenture placement.

Implant Indications	
Standard Diameter	Narrow Diameter
<ul style="list-style-type: none"> • Patients with sufficient bone volume to accommodate a standard diameter implant • Minimally invasive or standard flap procedures • Low or high bone density • Younger patients • Individuals who may wish to convert from an implant overdenture to a fixed restoration 	<ul style="list-style-type: none"> • Patients with narrow ridges that cannot accommodate a standard implant without complex surgical procedures • Minimally invasive surgical procedures • High bone density • Older patients • Individuals who are satisfied with complete dentures and are looking for a solution to stabilize a loose denture

Table 3: Indications of standard and narrow diameter implants.

the crest has been reported as $5.29\text{mm} \pm 2.37\text{mm}$ in the anterior region, $6.77\text{mm} \pm 1.63\text{mm}$ in the premolar region, and $7.31\text{mm} \pm 2.16\text{mm}$ in the molar region.³⁵ The crestal bone resorbs at a faster rate than the bone below the crest, due to interrupted blood supply after surgery, tooth loss, and occlusal pressure from the forces of mastication.

Ensuring adequate bone at the implant-placement site is important when treatment planning. Table 2 lists minimum bone-volume recommendations when placing standard and narrow diameter implants. For treatment-planning purposes, a 3.4mm standard diameter dental implant requires a minimum of 6.4mm in buccal-lingual width, whereas a 2.4mm narrow diameter implant requires a minimum of 5.4mm in width (Fig. 5).

Prosthetic Space Treatment Considerations

Implant overdentures require space to contain the attachment, denture attachment apparatus, acrylic resin,

and teeth. This prosthetic space is further bound by the occlusal plane, supporting tissues of the edentulous arch, and non-supporting tissues such as the cheeks, tongue, and lips.³⁶ The minimum height required for a LOCATOR Abutment and attachment for either a standard or narrow diameter implant is 9-11mm from the bone crest to the polished cameo surfaces or incisal edge of the denture (Fig. 6). If the prosthetic space is insufficient, the alveolar ridge can be re-contoured to create sufficient room for the implant abutment and attachments.

For either standard or narrow diameter implants, it is essential to measure the soft-tissue height in order to choose the appropriate abutment (Fig. 7). Because multiple abutment heights are available for standard diameter implants, this step can be completed after the implants have been placed and are ready to restore. For narrow diameter implants, however, it should be completed with the assistance of bone sounding or

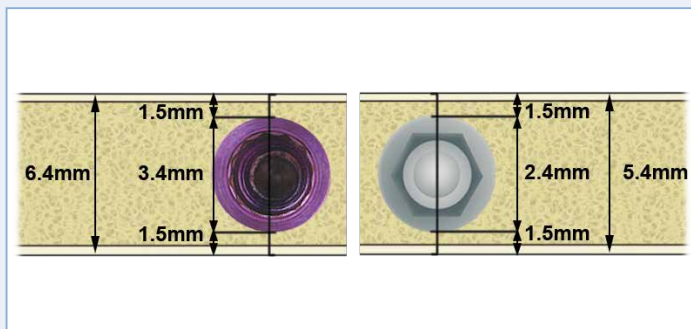


Fig. 5. Standard diameter implants require a minimum of 6.4mm in bone width and narrow diameter implants require a minimum of 5.4mm in bone width for proper placement and osseointegration.

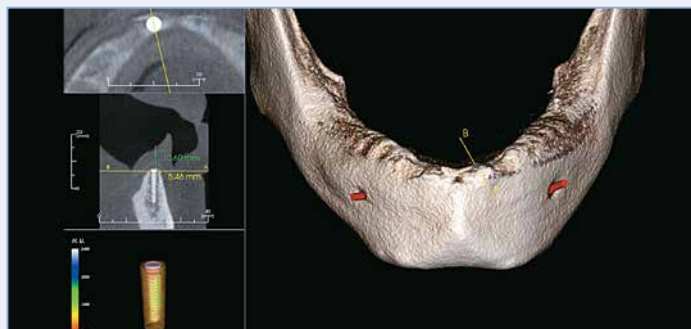


Fig. 7. Bone volume and prosthetic space for standard diameter implants is determined using cone-beam CT radiography.

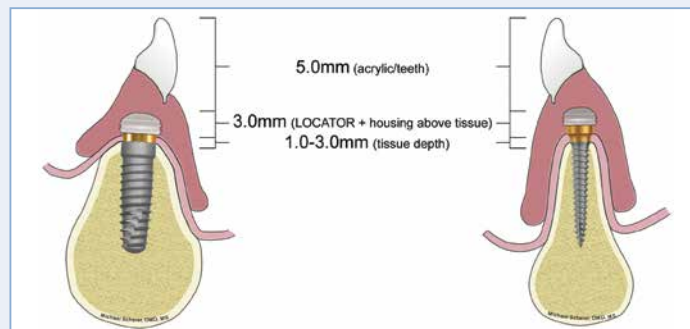


Fig. 6. LOCATOR® Abutments for either standard or narrow diameter implants require a minimum of 9-11mm of space from the crest of the bone to the surface of the denture.

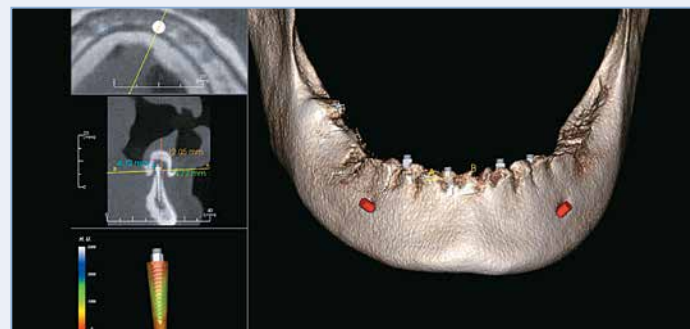


Fig. 8. Bone volume for narrow diameter implants and soft-tissue height measurements can be determined with cone-beam CT radiography and a radiopaque PVS and cotton-roll tissue separation.

measurement via cone-beam CT radiography prior to implant placement (Fig. 8). Many narrow diameter implant systems offer a single (or very few) abutment height options. Evaluation of tissue depth is easily performed by using a tool to measure from the alveolar ridge crest to the superior aspect of the tissue outline. This visualization is facilitated by using a radiopaque polyvinylsiloxane (PVS) liner inside the intaglio surface of the complete denture, with cotton rolls separating the oral tissues from the denture surface.³⁷⁻³⁹

Submerged Versus One-Stage Healing

Placement of standard or narrow implants can be accomplished either by flap elevation or a flapless procedure.^{32,37} When a flap must be raised, as in many cases where insufficient prosthetic space exists, alveolar bone recontouring is typically performed, and the implant is placed within the contours of the modified bone. The implant's primary stability is usually assessed by noting

the rotational resistance as the implant is inserted into the bone.⁴⁰ This resistance is related to minimization of implant movement during healing, and it promotes osseointegration.⁴¹ The amount of cortical bone at the placement site and the implant length are also related to primary implant stability.⁴² If alveolar ridge reduction is necessary, a substantial portion of the crestal cortical bone may be lost. Additionally, if sufficient healing time is not allowed after extractions, inadequate crestal bone cortical formation may be encountered during flapless surgical techniques.

If the implant's primary stability is insufficient, authors have advocated submerging the implant below the tissues to minimize occlusal loading.^{43,44} Standard diameter implants allow for submerged healing periods. However, narrow diameter implants typically only allow for transgingival, unsubmerged healing. If low implant insertion stability is encountered during surgical procedures for narrow

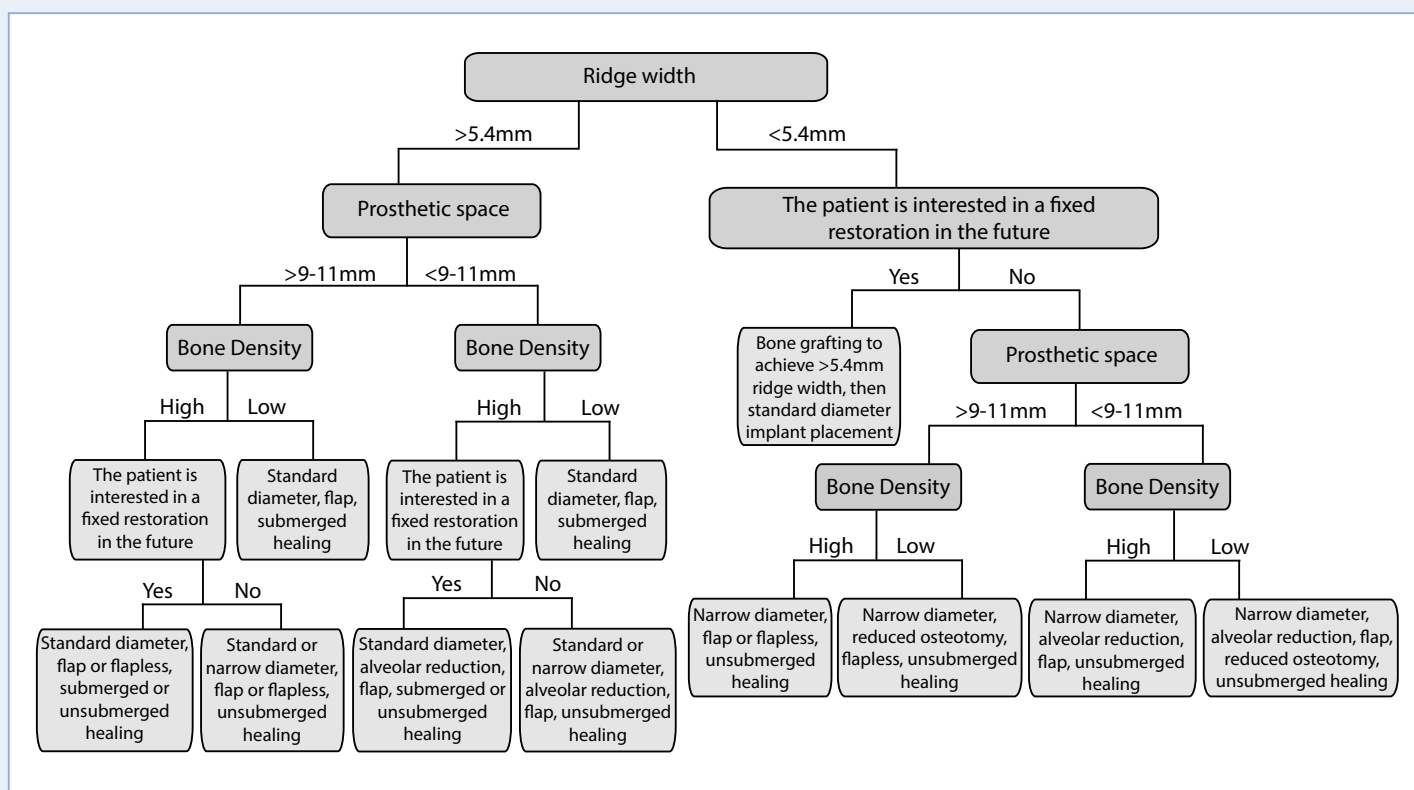


Fig. 9. Decision tree for choosing between standard and narrow diameter implants.

diameter implants, a soft liner can be applied to the inside of the denture to minimize the chances of premature occlusal loading.

Choosing between Standard and Narrow Diameter Implants

Deciding between placement of standard or narrow diameter implants to retain overdentures can be challenging. Under ideal conditions, both designs have features that enable them to stabilize a complete denture and improve patient satisfaction and quality of life. However, clinicians typically encounter both ideal and non-ideal situations.

Table 3 lists indications for standard and narrow diameter implants. Figure 9 offers a guide for facilitating the typical decision-making process. The principal deciding factor for choosing between a standard and narrow diameter implant is the alveolar ridge width. If the ridge cannot

accommodate an implant larger than 3mm, a narrow diameter implant may be indicated. However, if the ridge width can accommodate an implant larger than 3mm, either a standard or narrow diameter implant is generally indicated.

The next branch of the decision tree involves consideration of whether the patient is younger and/or may want to convert the implant overdenture into a fixed restoration in the future. If the patient has a ridge that is less than 5.4mm wide, and expresses interest in a future fixed option, alveolar bone grafting is indicated to create width sufficient to accommodate standard diameter implants. If the patient is uninterested in a future fixed option, a narrow diameter implant is generally indicated. The risks of the patient undergoing complex surgical procedures must be weighed against the likelihood that those procedures will substantially benefit the patient sometime in the future.

The next determining factor is whether sufficient prosthetic space exists within the patient's current prosthesis to accommodate the abutment, the attachment assembly, and approximately 2-3mm of acrylic resin surrounding these components. If the prosthetic space is insufficient, flap elevation and alveolar ridge recontouring is necessary to place either narrow or standard diameter implants. If sufficient prosthetic space exists, either standard or narrow diameter implants can be placed in a flapless procedure. When a patient presents with sufficient prosthetic space and narrow crestal alveolar ridge width, the clinician must decide whether to reduce the alveolar ridge to gain access to sufficient width to accommodate standard diameter implants or place a narrow diameter implant without surgically altering the ridge height. If sufficient prosthetic space and bone volume enable placement of narrow diameter implants without alveolar reduction procedures, a narrow diameter implant is indicated. High to average alveolar bone height has been linked to patient satisfaction.⁴⁵ Reducing the alveolar ridge height to accommodate a standard diameter implant when a narrow diameter implant would suffice is inadvisable.

Bone density is a critical factor for achieving implant primary stability. For patients who have alveolar ridge widths that are greater than 5.4mm but are Type III or IV bone density,⁴⁶ submerged healing with a standard diameter dental implant is indicated. For those with alveolar ridge widths less than 5.4mm but sufficient prosthetic space, a flapless procedure is indicated. However, the clinician would need to vary the surgical protocol to compensate for the lower bone density by reducing the osteotomy size. For patients with limited alveolar ridge width, high bone density, and limited prosthetic space, alveolar reduction and placement of narrow diameter implants is indicated. If bone densities are high for patients with alveolar ridge widths greater than 5.4mm, the patient should be asked about any possible interest in a future fixed restoration. Older patients who are principally interested in denture stabilization are good candidates for either standard or narrow diameter implants, so the choice of which to use depends upon the clinician's preference. The pros and cons of both standard and narrow diameter implant options should be discussed with the patient. For many people, the use of a minimally invasive surgical procedure is desirable and can be achieved with standard or narrow diameter implants. For many clinicians, particularly those who are new to implant dentistry, the allure of surgical simplicity and a high safety threshold makes narrow diameter implant placement desirable.

Conclusion

Deciding whether to use a standard or narrow diameter implant for treating edentulous patients can be challenging. Clinicians who evaluate patients interested in implant overdenture therapy need to consider a multitude of factors. The decision tree presented in this article is intended to facilitate the decision-making process. The surgical simplicity of narrow diameter implants is alluring to many clinicians.

References

1. Felton DA. Edentulism and comorbid factors. *J Prosthodont* 2009;18:88-96.
2. Breslow L. A quantitative approach to the World Health Organization definition of health: physical, mental, and social well-being. *Int J Epidemiol* 1972;4:347-355.
3. Carlsson GE, Omar R. The future of complete dentures in oral rehabilitation. A critical review. *J Oral Rehabil* 2010;37:143-156.
4. Douglass CW, Shih A, Ostry L. Will there be a need for complete dentures in the United States in 2020? *J Prosthet Dent* 2002;87:5-8.
5. Lang BR. A review of traditional therapies in complete dentures. *J Prosthet Dent* 1994;72:538-542.
6. Carlsson GE, Otterland A, Wennstrom A. Patient factors in appreciation of complete dentures. *J Prosthet Dent* 1967;17:322-328.
7. Gjengedal H, Berg E, Boe OE, et al. Self-reported oral health and denture satisfaction in partially and completely edentulous patients. *Int J Prosthodont* 2011;24:9-15.
8. Assunção WG, Barão VA, Delben JA, et al. A comparison of patient satisfaction between treatment with conventional complete dentures and overdentures in the elderly: a literature review. *Gerodontology* 2010;27:154-162.
9. Sadowsky SJ. Mandibular implant-retained overdentures: a literature review. *J Prosthet Dent* 2001;86:468-473.
10. Naert I, Alsaadi G, Quirynen M. Prosthetic aspects and patient satisfaction with two-implant-retained mandibular overdentures: a 10-year randomized clinical study. *Int J Prosthodont* 2004;17:401-410.
11. Shor A, Goto Y, Shor K. Mandibular two-implant-retained overdenture: prosthetic design and fabrication protocol. *Compend Contin Educ Dent* 2007;28:80-88.
12. Vercruyssen M, Marcelis K, Coucke W, et al. Long-term, retrospective evaluation (implant and patient-centred outcome) of the two-implants-supported overdenture in the mandible. Part I: survival rate. *Clin Oral Implants Res* 2010;21:357-365.
13. Feine JS, Carlsson GE, Awad MA, et al. The McGill consensus statement on overdentures. Mandibular two-implant overdentures as first choice standard of care for edentulous patients. *Int J Oral Maxillofac Implants* 2002;17:601-602.
14. Thomason JM, Kelly SA, Bendkowski A, et al. Two implant retained overdentures – a review of the literature supporting the McGill and York consensus statements. *J Dent* 2012;40:22-34.
15. Das KP, Jahangiri L, Katz RV. The first-choice standard of care for an edentulous mandible: a Delphi method survey of academic prosthodontists in the United States. *J Am Dent Assoc* 2012;143:881-889.

16. Misch CE, Crawford EA. Predictable mandibular nerve location--a clinical zone of safety. *Int J Oral Implantol* 1990;7:37-40.
17. Greenstein G, Tarnow D. The mental foramen and nerve: clinical and anatomical factors related to dental implant placement: a literature review. *J Periodontol* 2006;77:1933-1943.
18. Scherer MD, McGlumphy EA, Seghi RR, et al. Comparison of retention and stability of two implant-retained overdentures based on implant location. *J Prosthet Dent* 2014;112:515-521.
19. Scherer MD, McGlumphy EA, Seghi RR, et al. Comparison of retention and stability of implant-retained overdentures based upon implant number and distribution. *Int J Oral Maxillofac Implants* 2013;28:1619-1628.
20. Mraiwa N, Jacobs R, van Steenberghe D, et al. Clinical assessment and surgical implications of anatomic challenges in the anterior mandible. *Clin Implant Dent Relat Res* 2003;5:219-225.
21. Fanuscu MI, Chang TL. Three-dimensional morphometric analysis of human cadaver bone: microstructural data from maxilla and mandible. *Clin Oral Implants Res* 2004;15:213-218.
22. Kim JE, Shin JM, Oh SO, et al. The three-dimensional microstructure of trabecular bone: Analysis of site-specific variation in the human jaw bone. *Imaging Sci Dent* 2013;43:227-233.
23. Sadowsky SJ. Treatment considerations for maxillary implant overdentures: a systematic review. *J Prosthet Dent* 2007;97: 340-348.
24. Preoteasa E, Melescanu-Imre M, Preoteasa CT, et al. Aspects of oral morphology as decision factors in mini-implant supported overdenture. *Rom J Morphol Embryol* 2010;51:309-314.
25. al-Ansari BH, Morris RR. Placement of dental implants without flap surgery: A clinical report. *Int J Oral Maxillofac Implants* 1998;13:861-865.
26. Lei Q, Chen J, Jiang J, et al. Comparison of soft tissue healing around implants in beagle dogs: flap surgery versus flapless surgery. *Oral Surg Oral Med Oral Pathol Oral Radiol* 2013;115:e21-27.
27. Rath N, Scherer MD, McGlumphy E. Stabilization of a computer aided implant surgical guide using existing dental implants with conversion of an overdenture to a fixed prosthesis. *J Prosthodont* 2014;23:634-8.
28. Tarnow DP, Magner AW, Fletcher P. The effect of the distance from the contact point to the crest of bone on the presence or absence of the interproximal dental papilla. *J Periodontol* 1992;63:995-996.
29. Tarnow DP, Cho SC, Wallace SS. The effect of inter-implant distance on the height of inter-implant bone crest. *J Periodontol* 2000;71:546-549.
30. Spray JR, Black CG, Morris HF, et al. The influence of bone thickness on facial marginal bone response: Stage 1 placement through stage 2 uncovering. *Ann Periodontol* 2000;5:119-128.
31. Wilderman MN. Repair after a periosteal retention procedure. *Journal of Periodontology* 1963;34:487-503.
32. Becker W, Dahlin C, Becker BE, et al. The use of e-PTFE barrier membranes for bone promotion around titanium implants placed into extraction sockets: a prospective multicenter study. *Int J Oral Maxillofac Implants* 1994;9:31-40.
33. Gher ME, Quintero G, Sandifer JB, et al. Combined dental implant and guided tissue regeneration therapy in humans. *Int J Periodontics Restorative Dent* 1994;14:332-347.
34. Nir-Hadar O, Palmer M, Soskolne WA. Delayed immediate implants: Alveolar bone changes during the healing period. *Clin Oral Implants Res* 1998;9:26-33.
35. Katranji A, Misch K, Wang HL. Cortical bone thickness in dentate and edentulous human cadavers. *J Periodontol* 2007;78:874-878.
36. Ahuja S, Cagna DR. Classification and management of restorative space in edentulous implant overdenture patients. *J Prosthet Dent* 2011;105:332-337.
37. Scherer MD, Ingel AP, Rath N. Flapped or flapless surgery for narrow diameter implant placement for overdentures: advantages, disadvantages, indications, and clinical rationale. *Int J Periodontics Restorative Dent* 2014;34 Suppl:89-95.
38. Scherer MD. Presurgical implant-site assessment and restoratively driven digital planning. *Dent Clin North Am* 2014;58:561-595.
39. Scherer MD. Are radiographic guides necessary? A paradigm shift in implant site assessment, digital planning, and surgical guide fabrication. *Dent Today* 2014;33:62-67.
40. Friberg B, Sennerby L, Gröndahl K, et al. On cutting torque measurements during implant placement: A 3-year clinical prospective study. *Clin Implant Dent Relat Res* 1999;1:75-83.
41. Trisi P, Perfetti G, Baldoni E, et al. Implant micromotion is related to peak insertion torque and bone density. *Clin Oral Implants Res* 2009;20:467-471.
42. Hong J, Lim YJ, Park SO. Quantitative biomechanical analysis of the influence of the cortical bone and implant length on primary stability. *Clin Oral Implants Res* 2012;23:1193-1197.
43. Beer A, Gahleitner A, Holm A, et al. Correlation of insertion torques with bone mineral density from dental quantitative CT in the mandible. *Clin Oral Implants Res* 2003;14:616-620.
44. Schnitman PA, Hwang JW. To immediately load, expose, or submerge in partial edentulism: a study of primary stability and treatment outcome. *Int J Oral Maxillofac Implants* 2011;26:850-859.
45. Kimoto K, Garrett NR. Effect of mandibular ridge height on masticatory performance with mandibular conventional and implant-assisted overdentures. *Int J Oral Maxillofac Implants* 2003;18:523-530.
46. Lekholm U, Zarb GA. Patient selection. In: Brånemark PI, Zarb GA, Albrektsson T, editors. *Tissue-integrated prostheses. Osseointegration in clinical dentistry*. Chicago: Quintessence; 1985. p. 199-209.

In support of their research or for preparation of their work, one or more of the authors of the publications cited in the references may have received financial remuneration from BIOMET 3i LLC.

Michael D. Scherer, DMD, MS[†]



Dr. Scherer received his dental degree from Nova Southeastern University in Ft. Lauderdale, FL and his Masters of Science and Graduate Certificate in Prosthodontics from Ohio State University in Columbus, OH. He is a fellow of the American College of Prosthodontists, an Assistant Clinical Professor at Loma Linda University, and a Clinical Instructor at the University of Nevada, Las Vegas. Dr. Scherer maintains a private practice limited to prosthodontics and implant dentistry in Sonora, CA. Email: mds@scherer.net

[†] The contributing clinician has a financial relationship with BIOMET 3i LLC and ZEST Anchors LLC resulting from speaking engagements, consulting engagements, and other retained services.

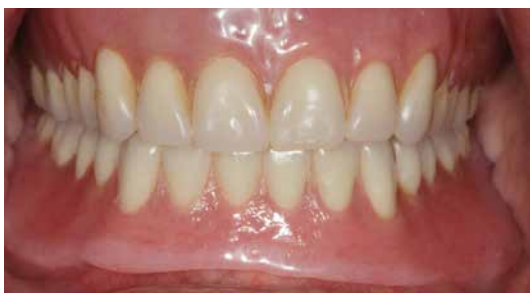ZEST Anchors LLC products are distributed by BIOMET 3i LLC.

Flapless placement of four narrow diameter implants to immediately stabilize a loose mandibular denture

Michael D. Scherer, DMD, MS[†] and Andrew P. Ingel, DMD

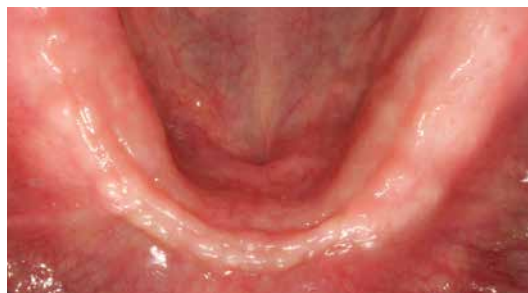A 65-year-old edentulous male patient presented with a chief concern of the inability to eat and lack of confidence due to a loose mandibular denture. A radiopaque PVS liner was placed into the intaglio surface of the denture, and a cone-beam computed tomographic (CBCT) scan with cotton-roll tissue separation was made to facilitate visualization of the denture and implant sites. A treatment plan was developed to place four 2.9mm LOCATOR® Overdenture Implants (LODI's) and immediately stabilize the loose mandibular denture.

Fig. 1



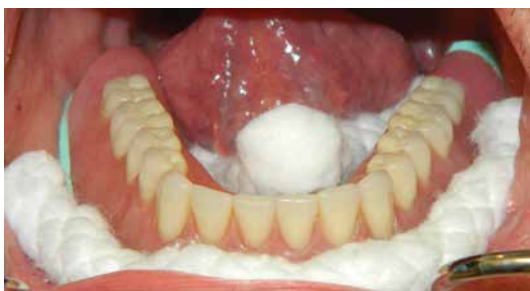The patient was edentulous and wearing tissue-supported removable dentures.

Fig. 2



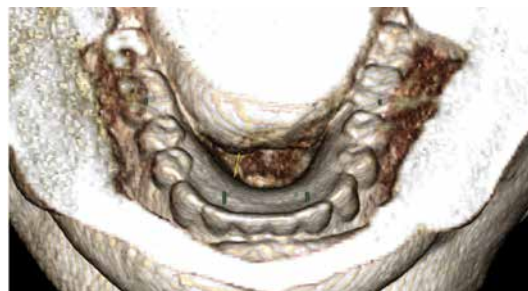
Examination revealed a narrow anterior mandibular ridge with adequate keratinized tissues.

Fig. 3



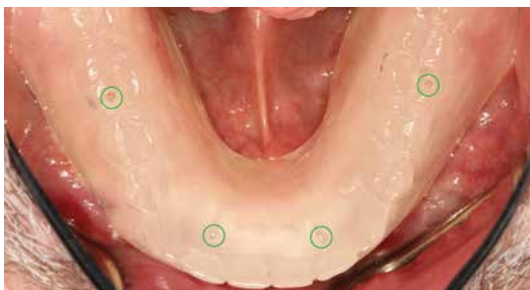Radiopaque PVS liner was applied to the intaglio surface of the mandibular denture, which was then placed onto the edentulous ridge and separated from the soft tissues using cotton rolls.

Fig. 4



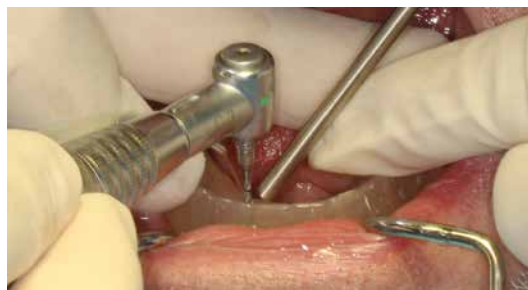A CBCT scan was taken and used to digitally plan the placement of four 2.9mm narrow diameter implants.

Fig. 5



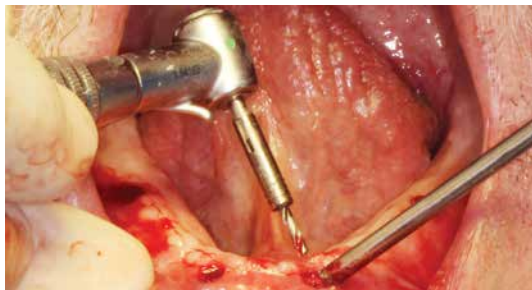A duplicate of the mandibular denture was fabricated and pilot holes (green circles) were created in conformance with the long axes of the digitally planned implants.

Fig. 6



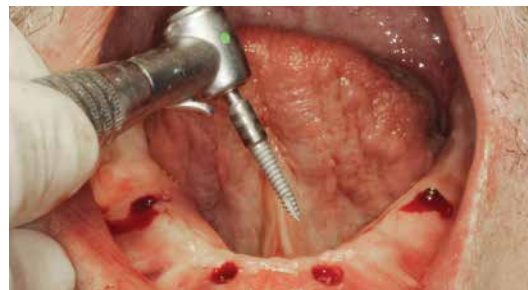The guide was placed onto the edentulous ridge, and the initial osteotomies were created using a pilot drill through the guide.

Fig. 7



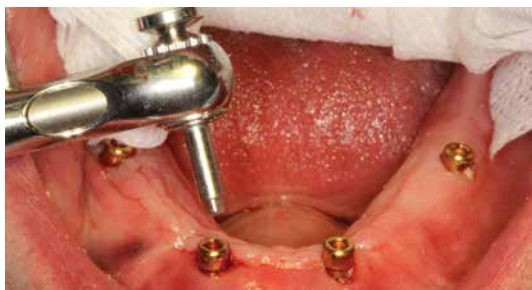Drills were used to sequentially increase the diameter of the osteotomies prior to implant placement.

Fig. 8



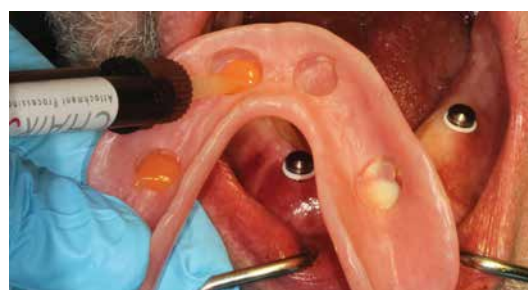2.9mm LODI's were initially placed using a handpiece. Full insertion was completed using a torque-indicating device to verify torque values >30Ncm.

Fig. 9



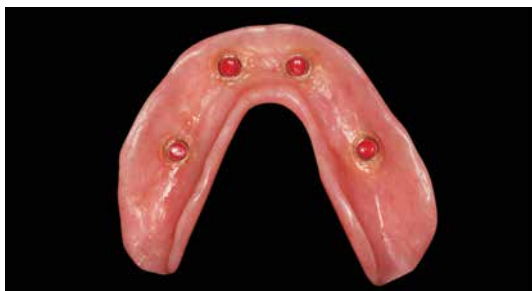LOCATOR® Abutments were placed onto the implants and torqued to 30Ncm. Block-Out Spacers and Denture Attachment Housings were placed on the abutments.

Fig. 10



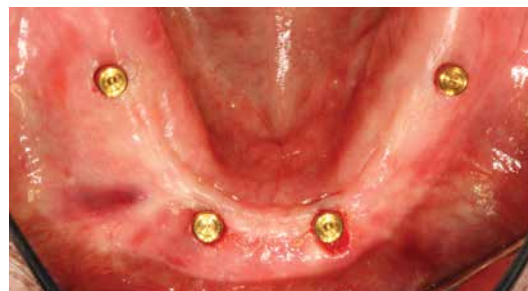CHAIRSIDE™ Attachment Processing Material was injected into recesses prepared in the intaglio surface of the denture.

Fig. 11



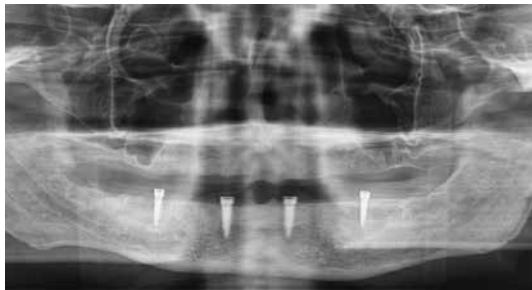After the resin polymerized, the denture was removed, and the processing inserts were replaced with retentive nylon inserts.

Fig. 12



Appearance of the LODI's immediately after placement.

Fig. 13



Radiographic confirmation of the final implant positions.

Michael D. Scherer, DMD, MS[†]

Dr. Scherer is an Assistant Clinical Professor at Loma Linda University and a Clinical Instructor at the University of Nevada, Las Vegas.

Andrew P. Ingel, DMD

Dr. Ingel is an Assistant Professor of Clinical Sciences and Director of Continuing Education at the University of Nevada, Las Vegas School of Dental Medicine.

[†]The contributing clinician has a financial relationship with BIOMET 3i LLC and ZEST Anchors LLC resulting from speaking engagements, consulting engagements, and other retained services.



THE MAKING OF A GOLD STANDARD



ZEST's LOCATOR® Implant Attachment System represents a rare occurrence in the implant field. Never before has the implant industry, clinicians, and patients come together to universally recognize the merits of a restorative solution. It has allowed LOCATOR to become the most globally recognized and trusted brand for overdenture restorations.



INDUSTRY WIDE SOLUTION

The dental implant companies that collectively make up over 90% of the global implant market supply partner with ZEST Anchors to make the LOCATOR Abutment compatible with their dental implants.



CLINICIAN PREFERENCE

LOCATOR's unique low profile design, pivoting technology, durability, and ease-of-use has propelled it to be the preferred choice of clinicians worldwide for implant-retained, tissue supported overdentures.



PATIENT SATISFACTION

Nearly two million patients are enjoying an improved quality of life by trusting their clinician to secure their restoration with LOCATOR.

TOGETHER WE CAN MAKE TOMORROW EVEN BETTER

The trust and confidence placed in ZEST since its inception in 1972 is not taken lightly. It enhances our company's commitment to our implant company partners, clinicians, and your patients. Together we will continue to provide more options for the treatment of patients who suffer from the real-life problems associated with edentulism.

Stay close to ZEST for soon-to-be released innovations that can improve and expand the clinical solutions available within the LOCATOR Portfolio of products.

To experience for yourself how LOCATOR became the Gold Standard of resilient attachment systems, please contact your local BIOMET 3i Sales Representative, visit www.biomet3i.com or call 1-800-342-5454.



©2015 ZEST Anchors LLC. All rights reserved.
LOCATOR and ZEST are registered trademarks of
ZEST IP Holdings, LLC. Providing Solutions - One
Patient At A Time is a trademark of BIOMET 3i LLC.
BIOMET 3i is a trademark of Biomet Inc.



ART1268
REV A 04/15

